

Patient ID : GScanlon052299
 Procedure : OCTReport
 Eye : OD(R)

Patient Name : Scanlon Graham
 Create Date : 12/30/2025
 Timer :

Print Date : 12/30/2025

TOPCON 3D Wide Report

Print Date: 12/30/2025

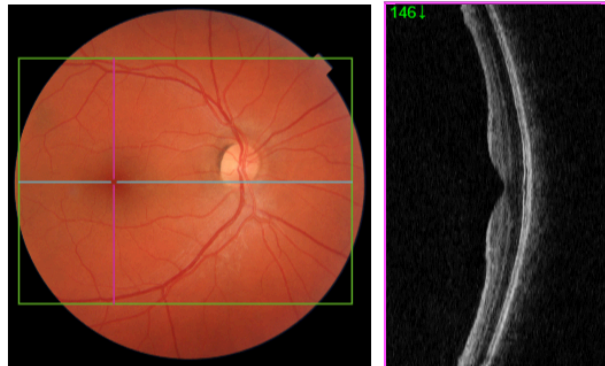
ID: GScanlon052299
Name: Graham Scanlon

Ethnicity:
 Gender:
 DOB: 05/22/1999 Age: 26

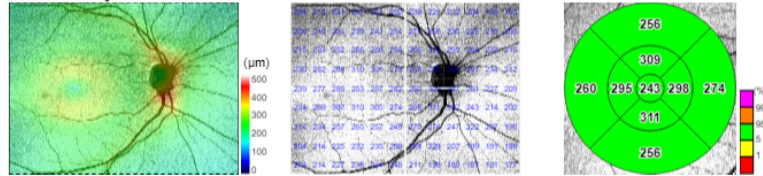
Technician:
 Fixation: Wide
 Scan: 3D(12.0x9.0mm - 512x128)

Maestro2

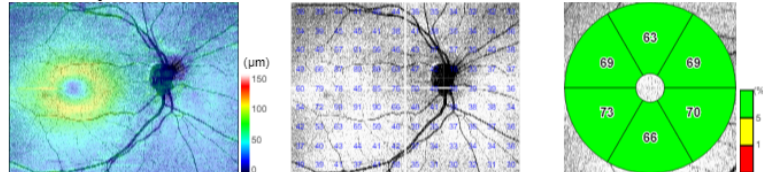
OD Image Quality: **37** Analysis mode: Fine (2.0.8)
 Capture Date: 12/30/2025



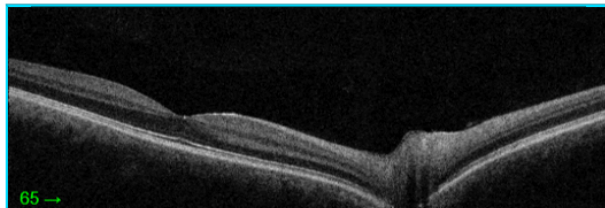
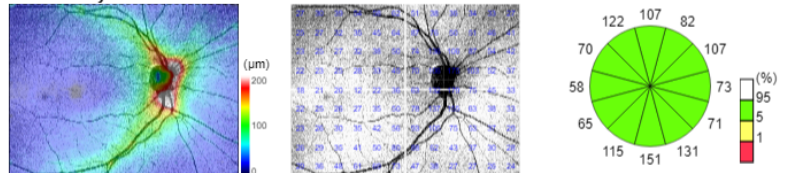
Retina Analysis



GCL+ Analysis



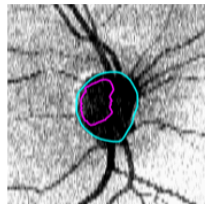
RNFL Analysis



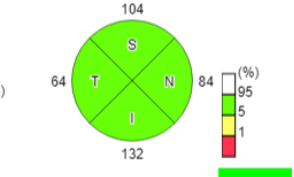
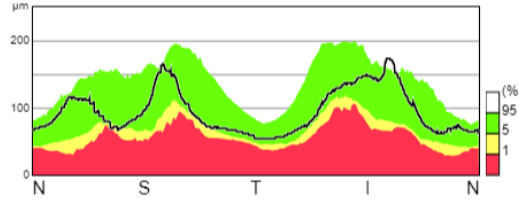
Disc Topography

Rim Area (mm ²)	1.10
Disc Area (mm ²)	1.67
Linear CDR	0.59
Vertical CDR	0.68
Cup Volume (mm ³)	0.07

Reference Plane Height: 120µm



Disc margin
 Cup margin



RNFL Average Thickness 96 µm

Comments:

Signature:

Date: